

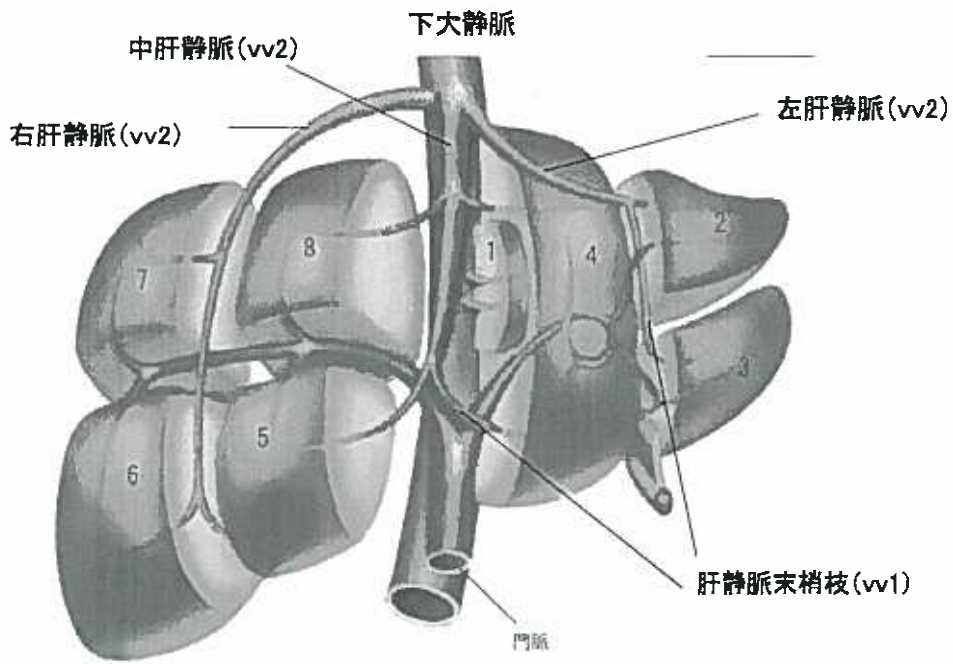図5 肝静脈の分岐

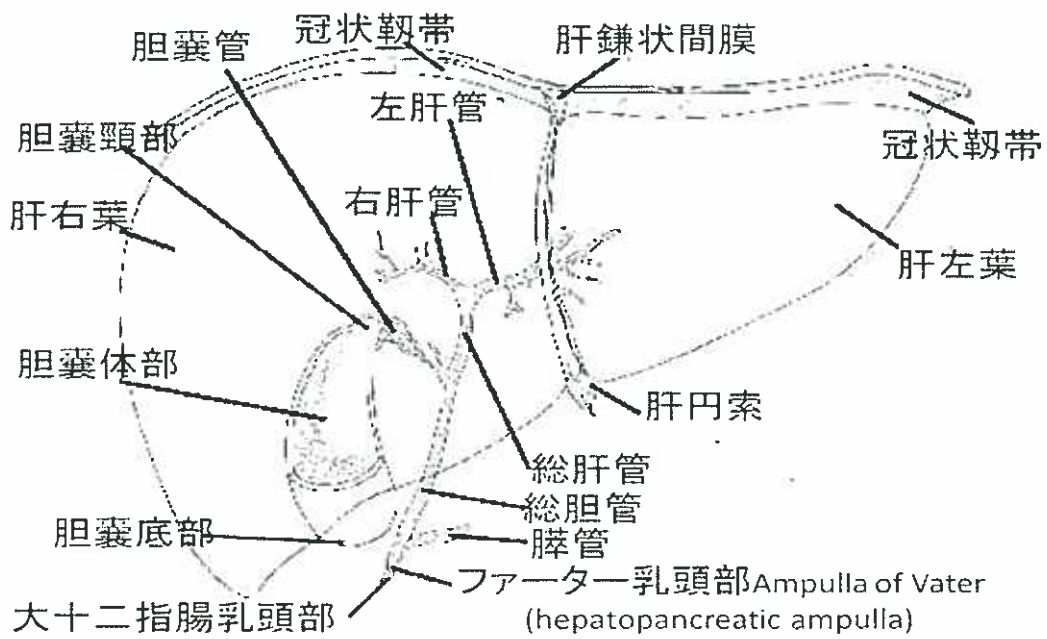


図6 胆道系の構造

4 肝内結石症手術／肝臓の脈管系

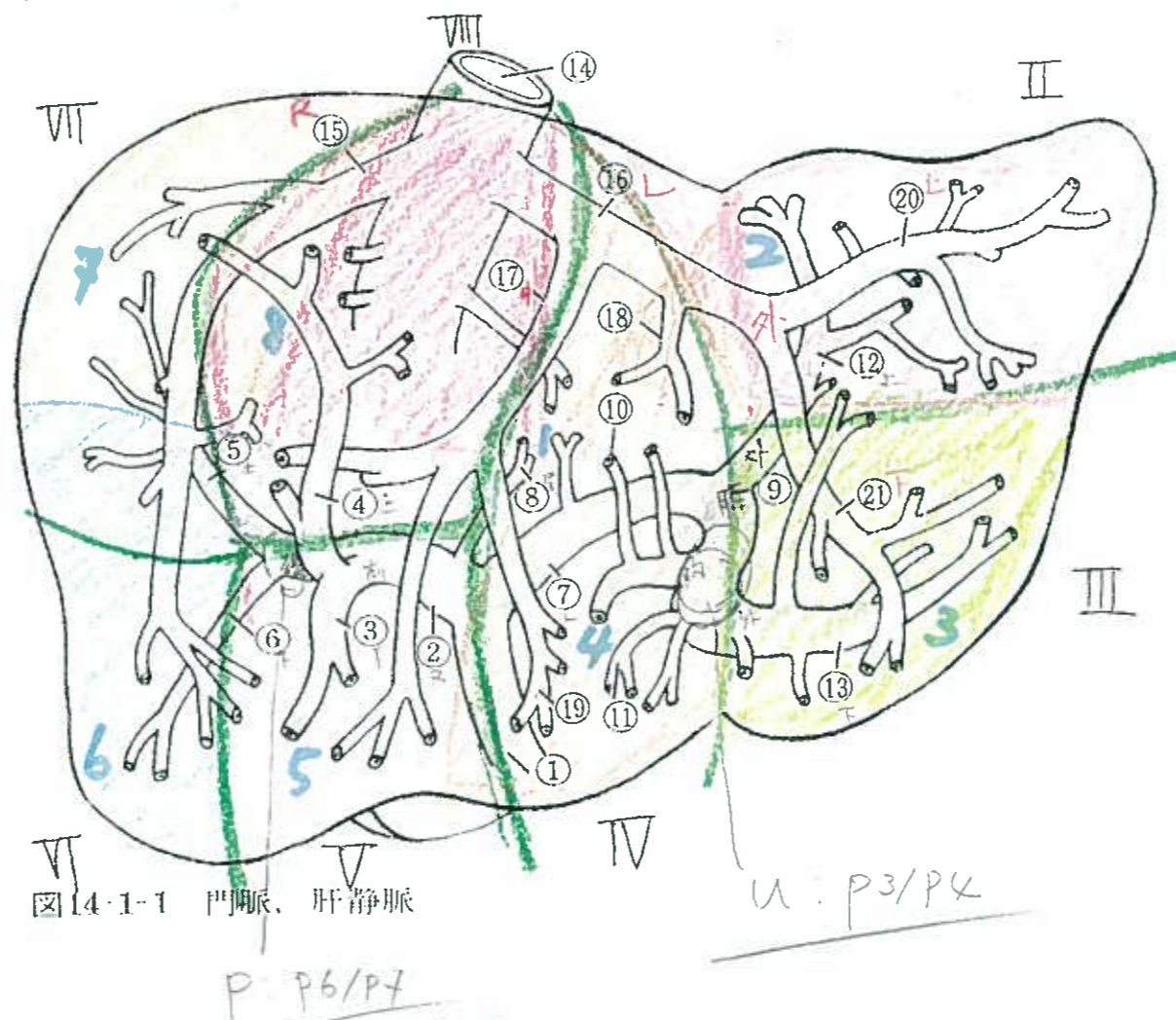


図14-1-1 門脈, 肝静脈

- ① 門脈 Portal vein
- ② 門脈右枝 Right branch of portal vein
- ③ 右前下行枝 Right anterior inferior portal vein
- ④ 右前上行枝 Right anterior superior portal vein
- ⑤ 右後上行枝 Right posterior superior portal vein
- ⑥ 右後下行枝 Right posterior inferior portal vein
- ⑦ 門脈左枝 Left branch of portal vein
- ⑧ 尾状葉枝 Caudate lobe veins
- ⑨ 臍部 Parumbilicalis of portal vein
- ⑩ 左内側上行枝 Left medial superior portal veins
- ⑪ 左内側下行枝 Left medial inferior portal veins
- ⑫ 左外側上行枝 Left lateral superior portal vein
- ⑬ 左外側下行枝 Left lateral inferior portal vein
- ⑭ 下大静脈 Inferior vena cava
- ⑮ 右肝静脈 Right hepatic vein
- ⑯ 左肝静脈 Left hepatic vein
- ⑰ 中肝静脈 Middle hepatic vein
- ⑱ 左中上肝静脈 Left middle superior hepatic vein
- ⑲ 左中下肝静脈 Left middle inferior hepatic vein
- ⑳ 左外上肝静脈 Left lateral superior hepatic vein
- ㉑ 左外下肝静脈 Left lateral inferior hepatic vein

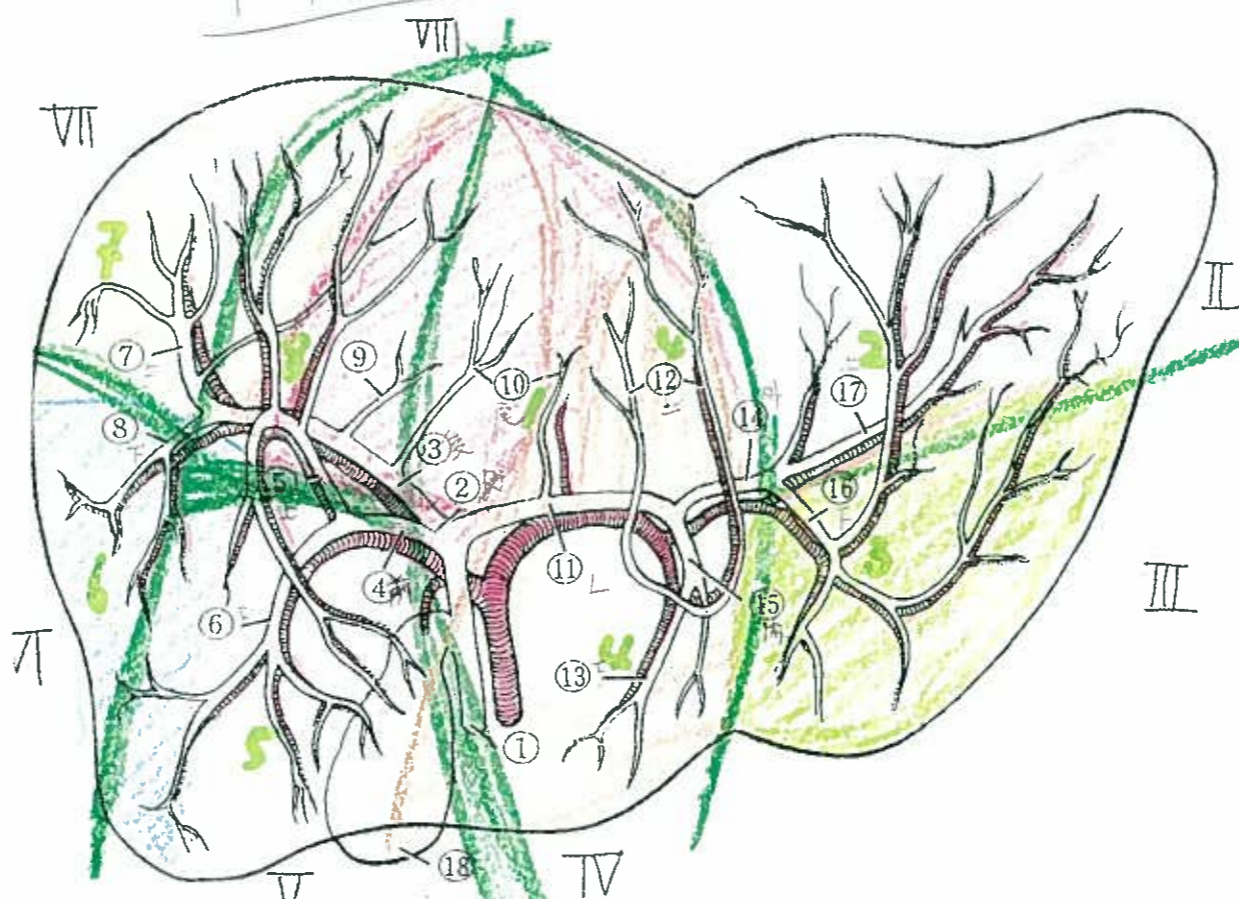


図14-1-2 胆管, 肝動脈

- ① 総胆管 Common bile duct
- ② 右肝管 Right hepatic duct
- ③ 後枝 Posterior segmental duct
- ④ 前枝 Anterior segmental duct
- ⑤ 前上行枝 Anterior superior duct
- ⑥ 前下行枝 Anterior inferior duct
- ⑦ 後上行枝 Posterior superior duct
- ⑧ 後下行枝 Posterior inferior duct
- ⑨ 突起枝 Caudate process duct
- ⑩ 尾状葉枝 Caudate lobe ducts (right and left)
- ⑪ 左肝管 Left hepatic duct
- ⑫ 内側上行枝 Medial superior ducts
- ⑬ 内側下行枝 Medial inferior ducts
- ⑭ 外側枝 Lateral segmental duct
- ⑮ 内側枝 Medial segmental duct
- ⑯ 外側下行枝 Lateral inferior duct
- ⑰ 外側上行枝 Lateral superior duct
- ⑱ 胆嚢 Gallbladder